

Αποτυχία – Υποτροπή...

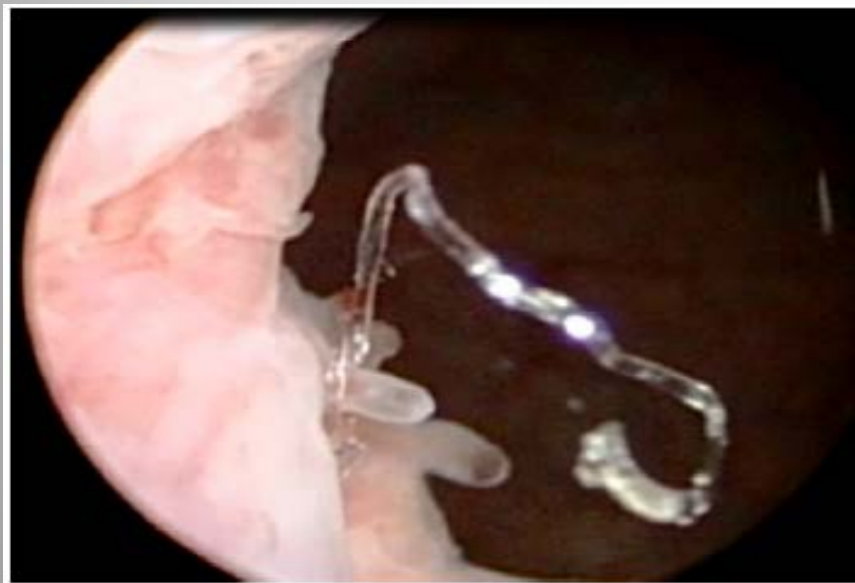
- Τι, ποιος, που???
- Ποια η ένδειξη?
- Ποια ήταν η ΜΤΧ εξέλιξη...?

Έλεγχος

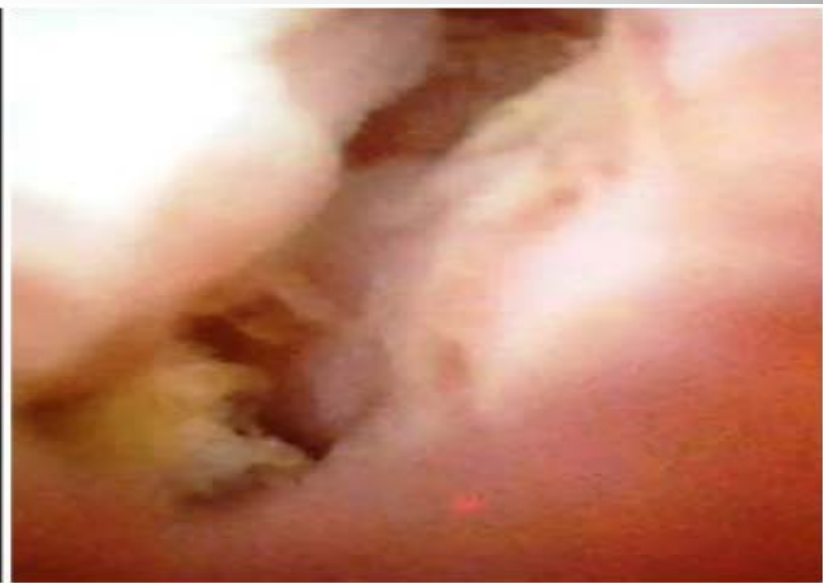
- Κλινική εξέταση
- Pelvic Echo
- Ουροδυναμικός έλεγχος!!!

Θεραπευτικές επιλογές

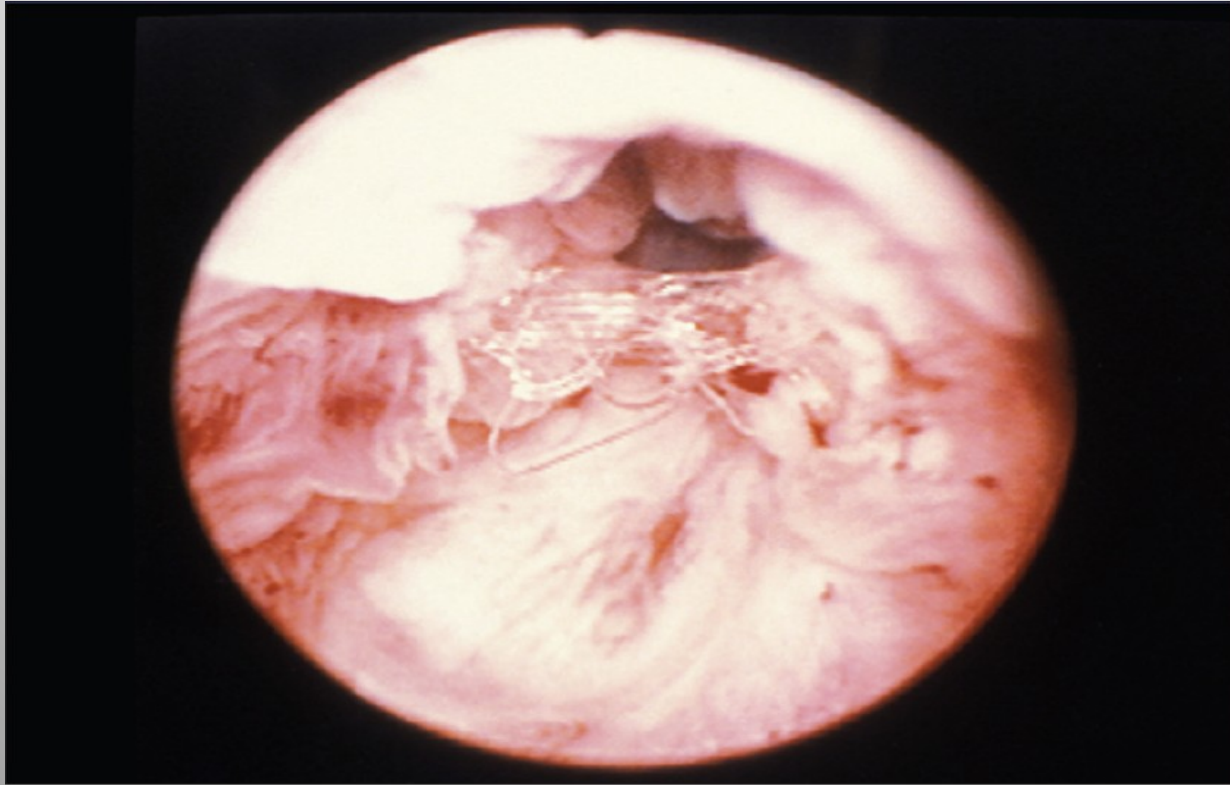
- Bulking agents (20-30%)
- Tightening the sling
- MUS
- Pubovaginal sling
- Burch
- Pro-ACT
- AUS 800
- Urinary diversion....



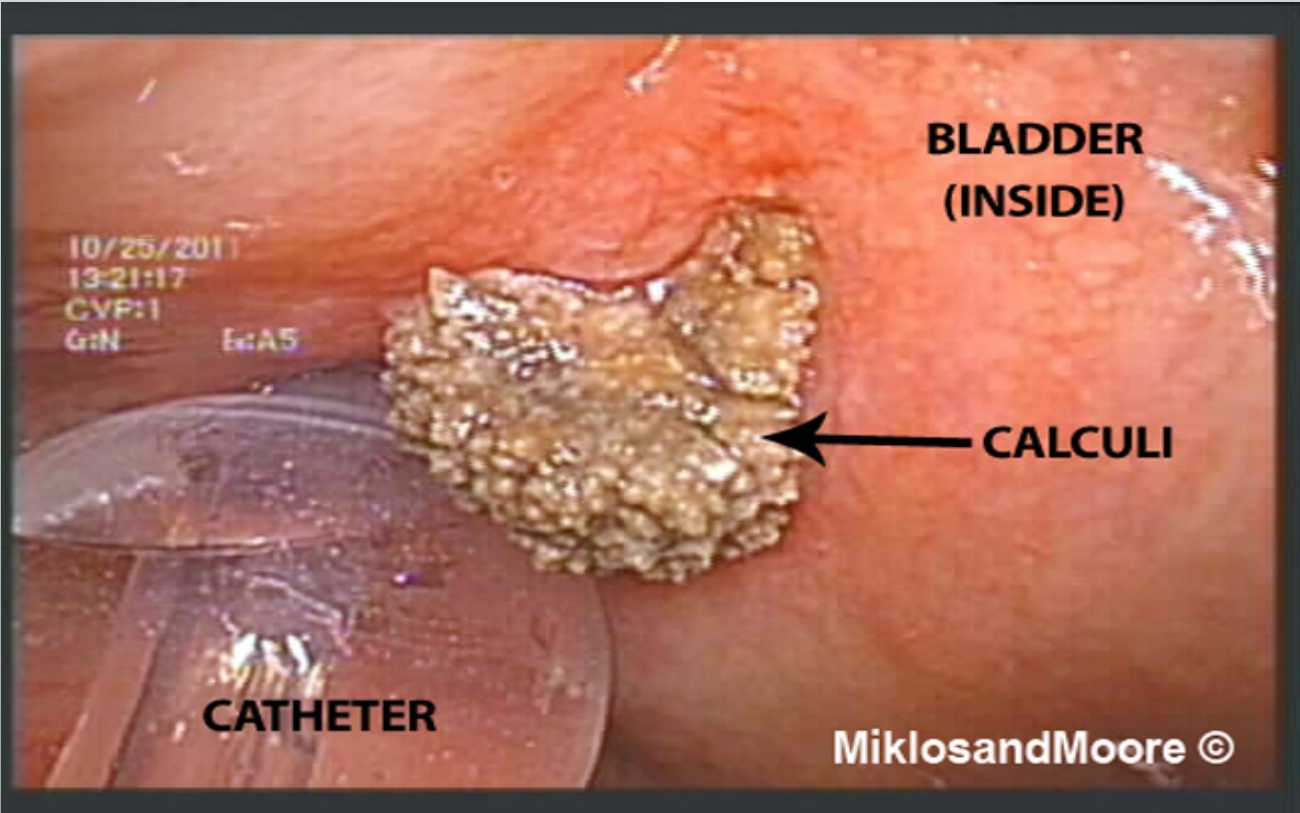
Προβολή υλικού στον αυχένα



Προβολή υλικού στην ουρήθρα







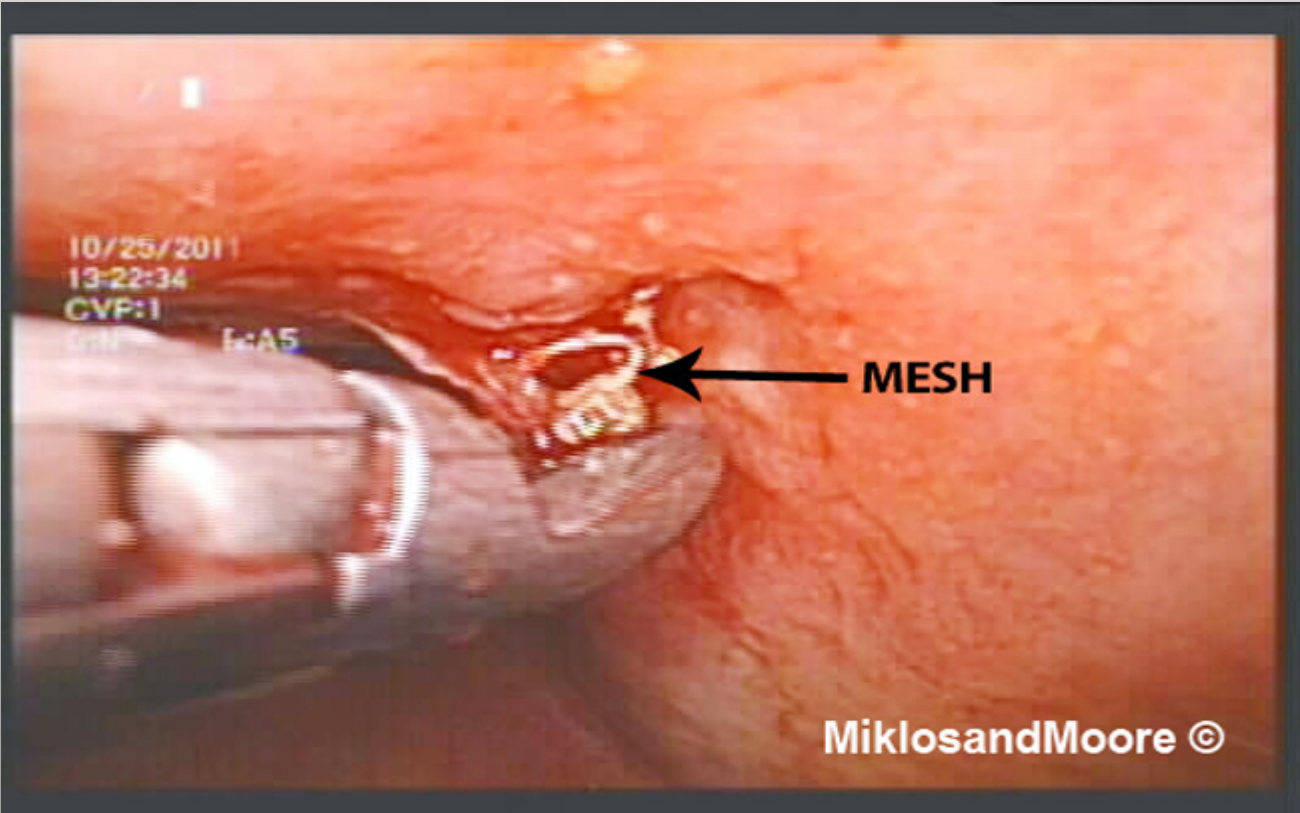
**BLADDER
(INSIDE)**

← CALCULI

CATHETER

10/25/2011
13:21:17
CVP:1
G:N E:AS

MiklosandMoore ©



10/25/2011

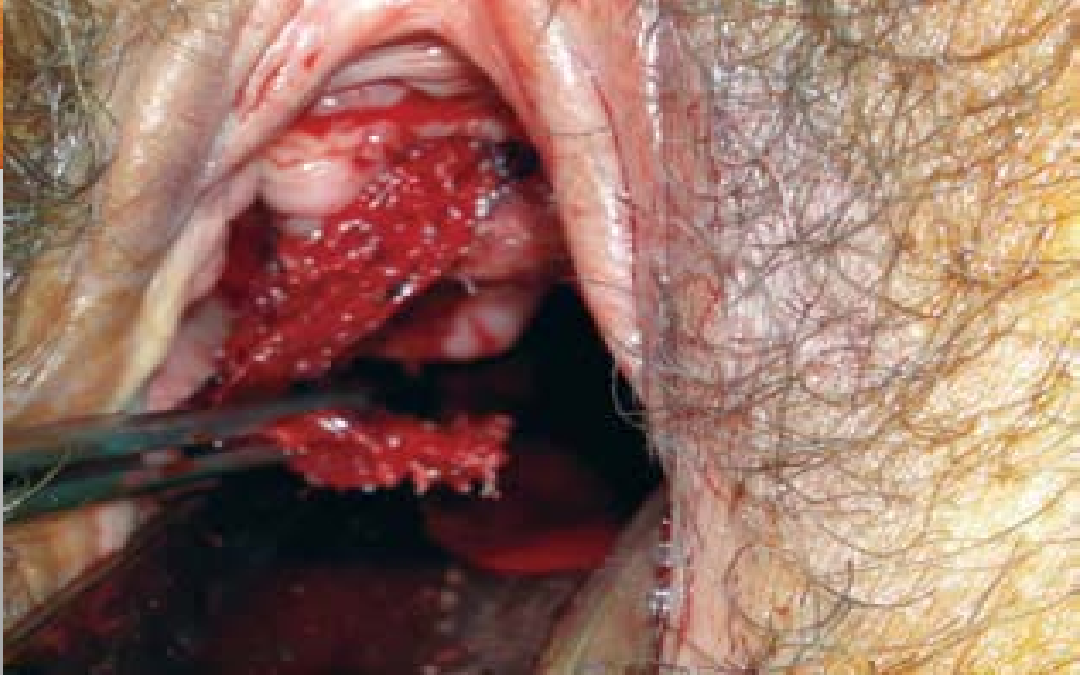
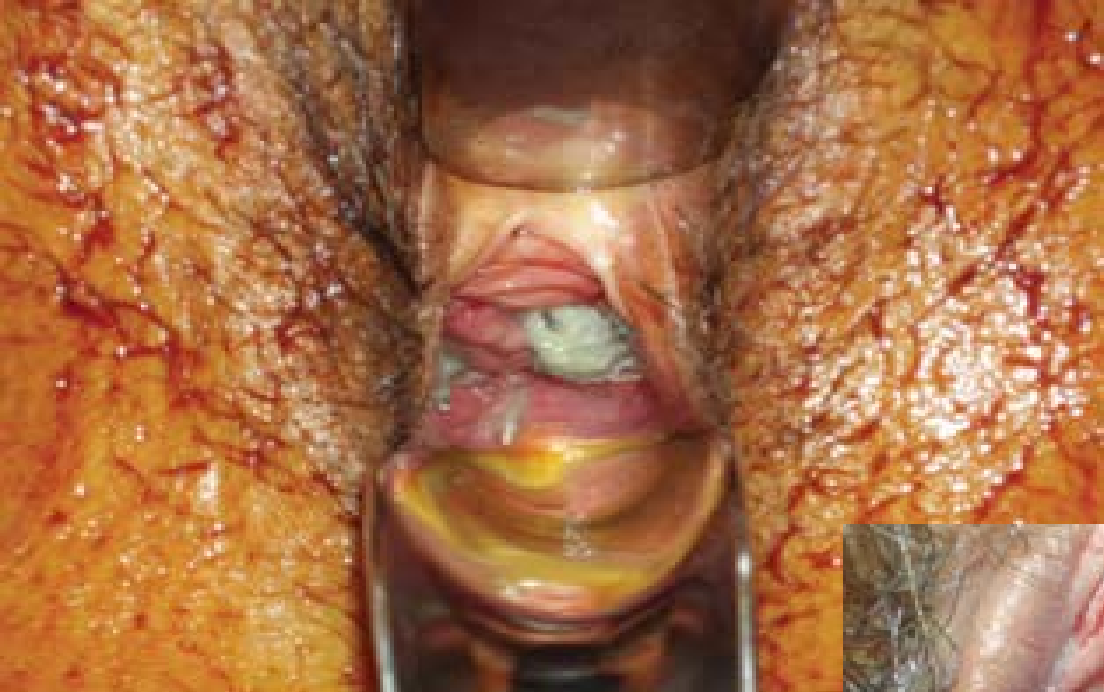
13:22:34

CVP:1

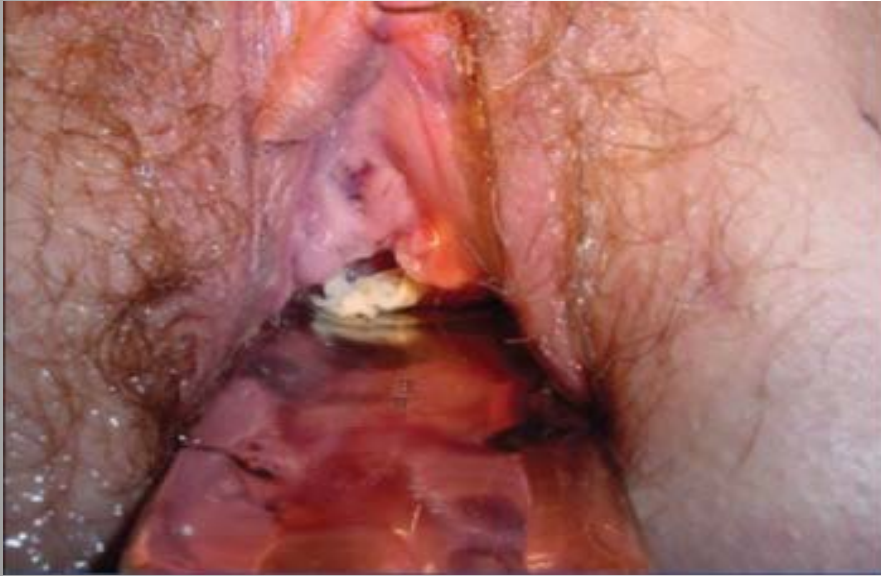E:A5

MESH

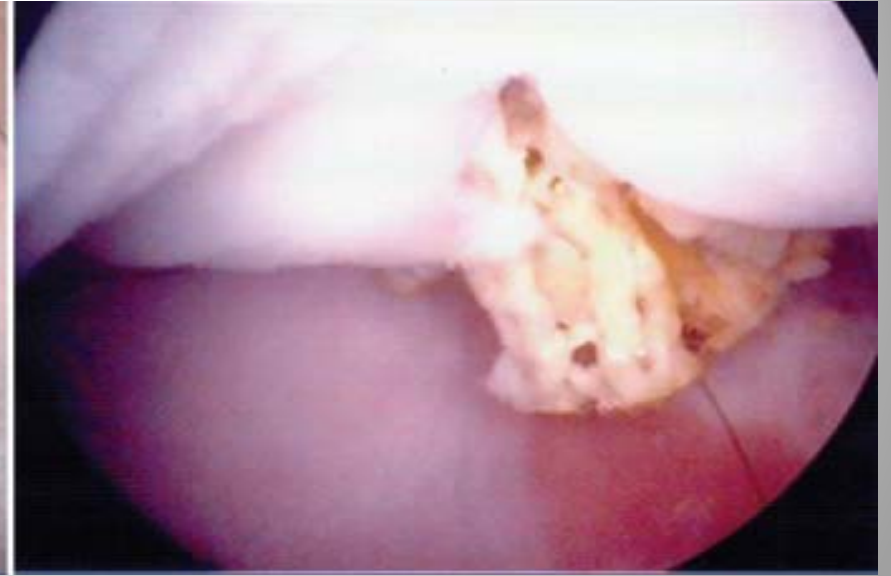MiklosandMoore ©



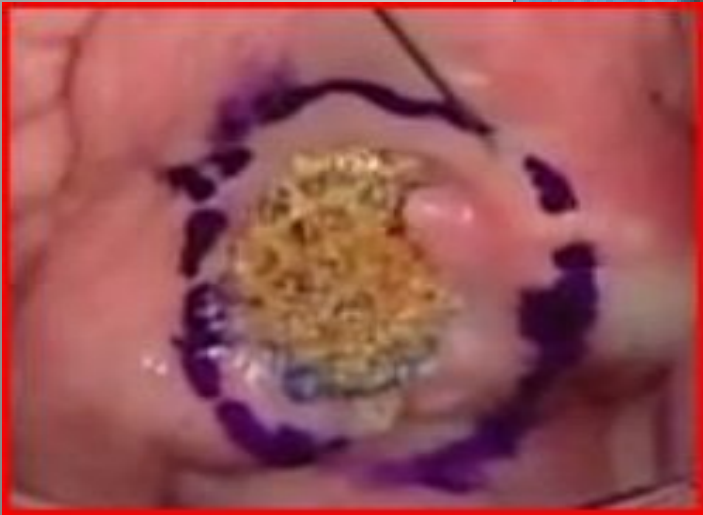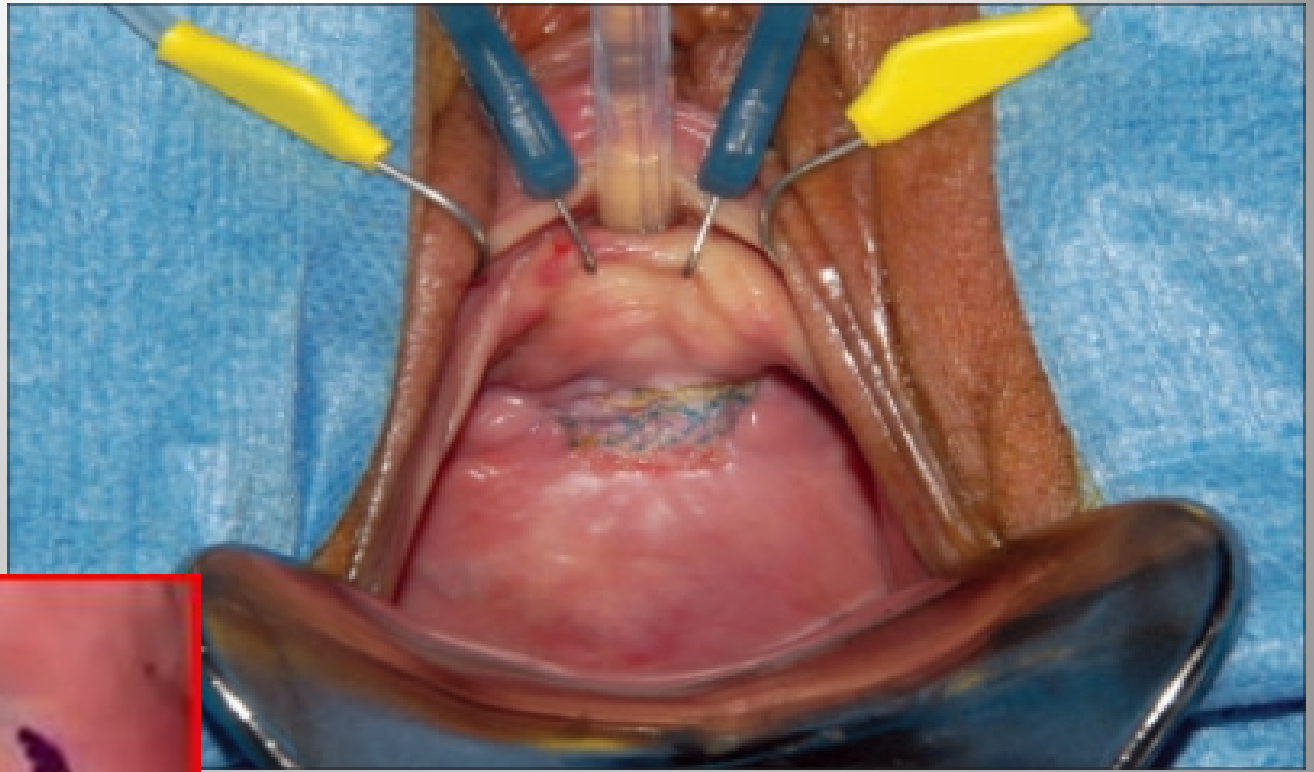
Προβολή υλικού στο πρόσθιο
κολπικό τοίχωμα



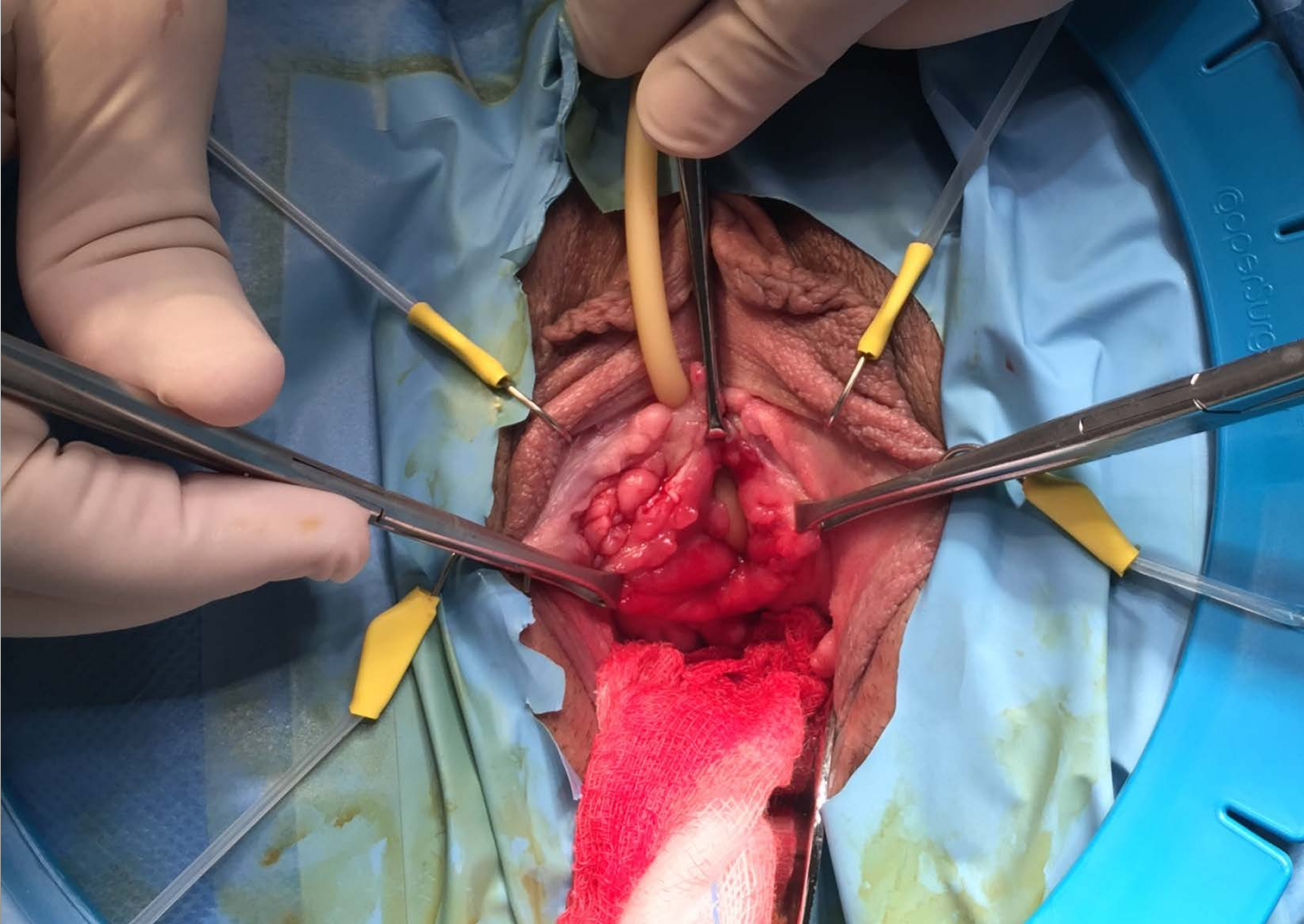
Προβολή υλικού στο πρόσθιο
κολπικό τοίχωμα

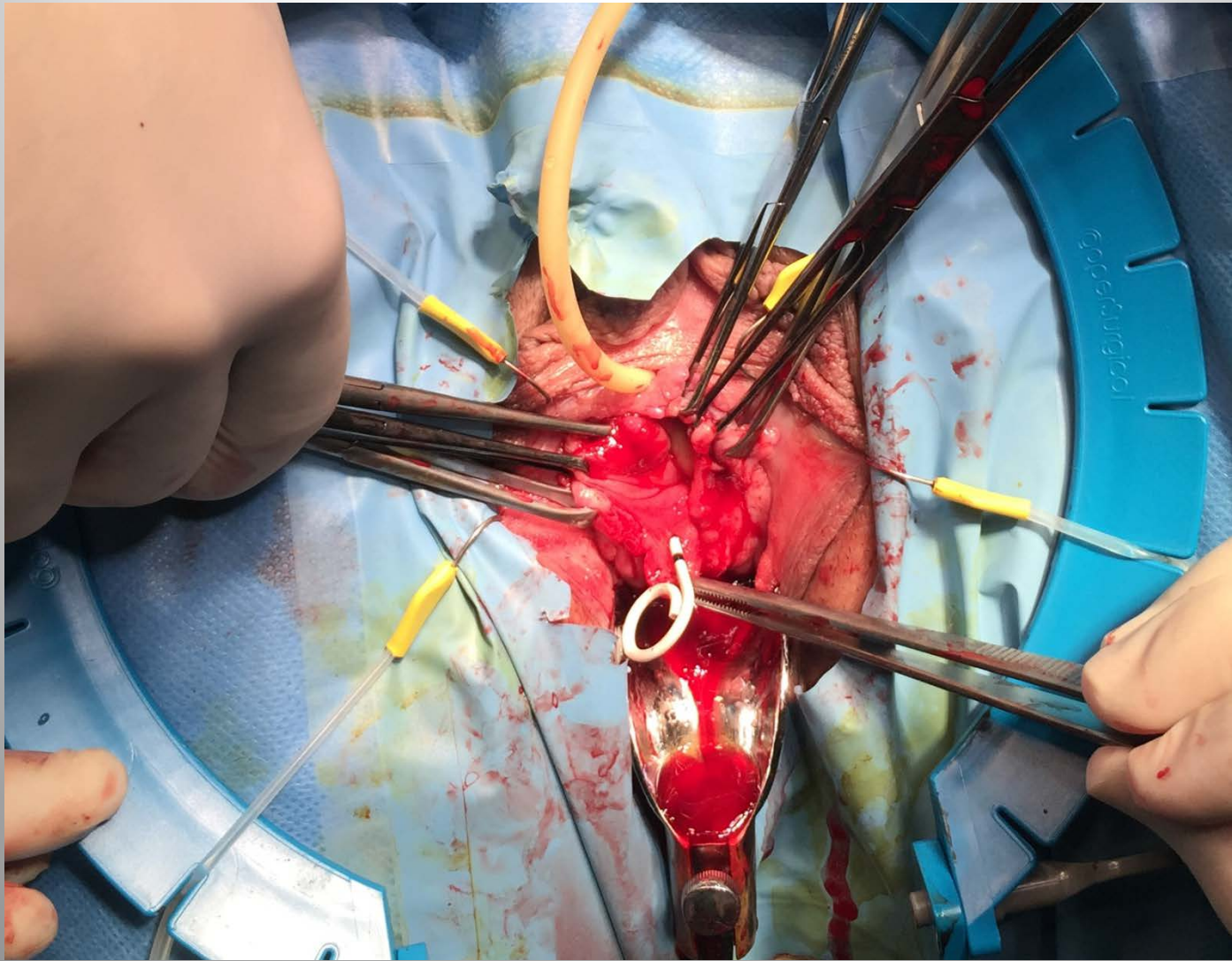


Ενδοσκοπική εικόνα
κολποσκόπησης

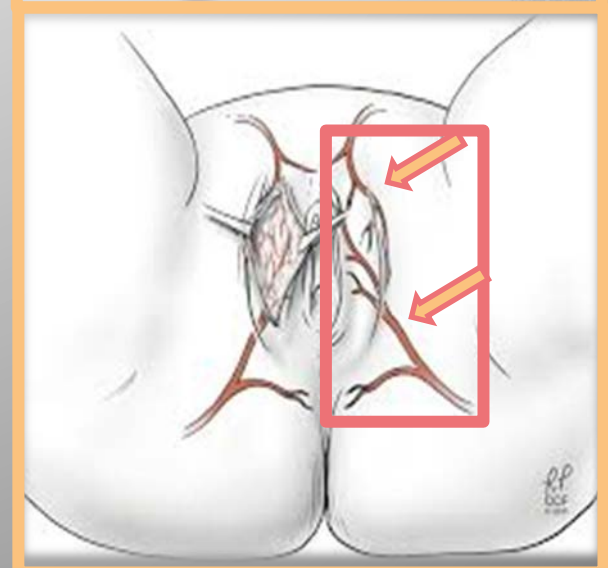
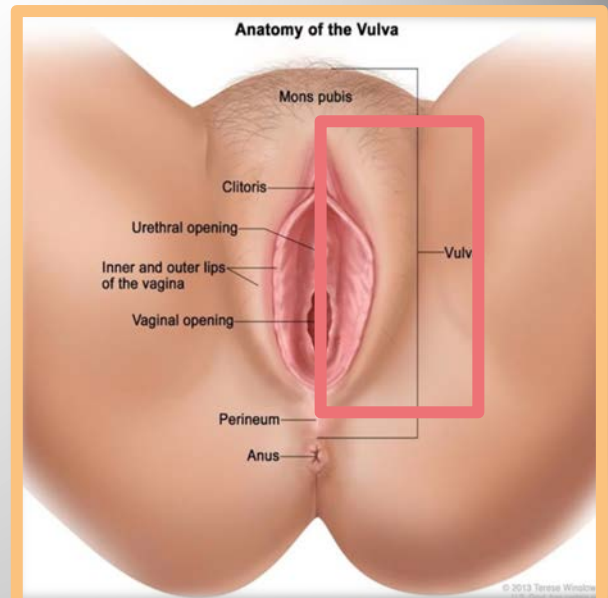
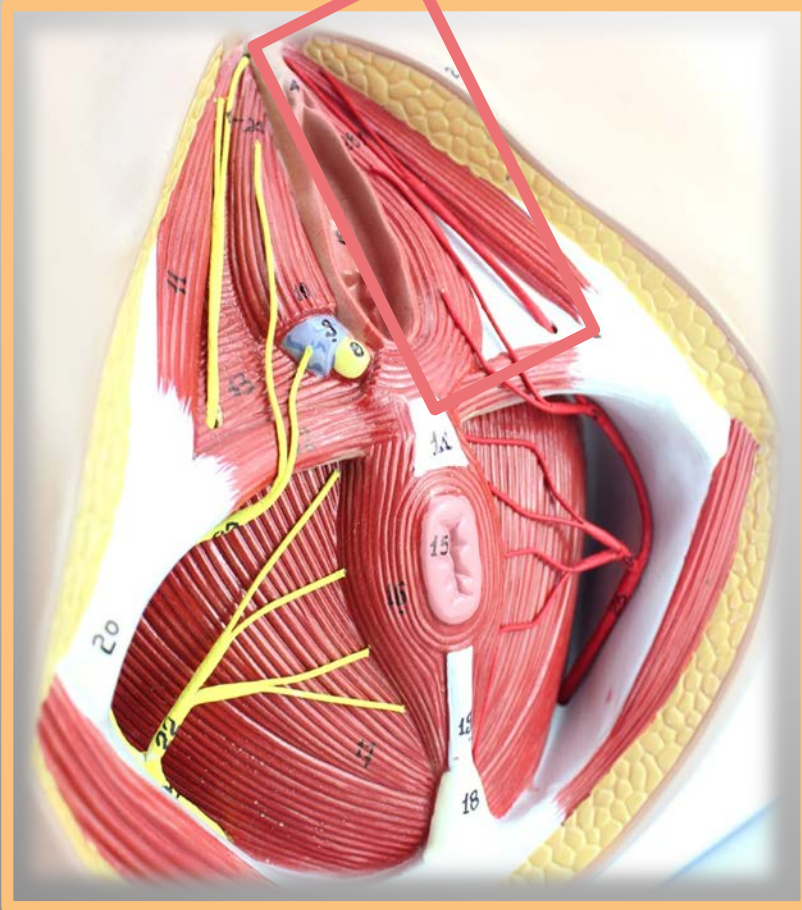


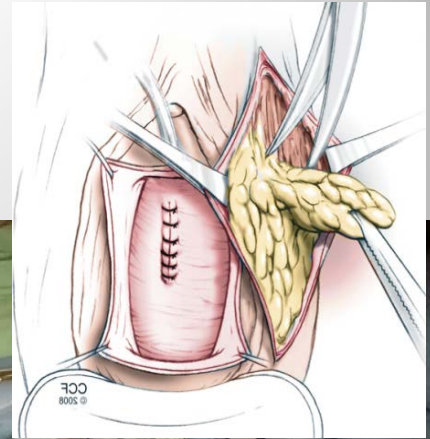
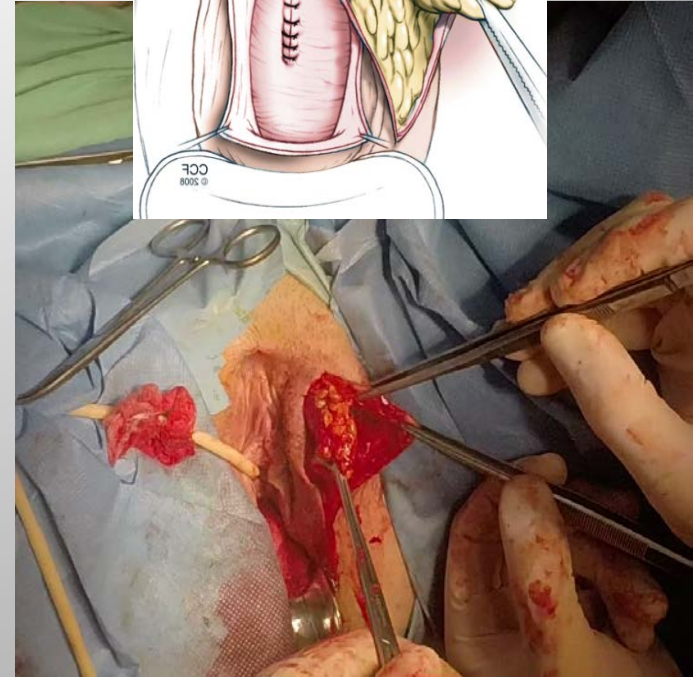
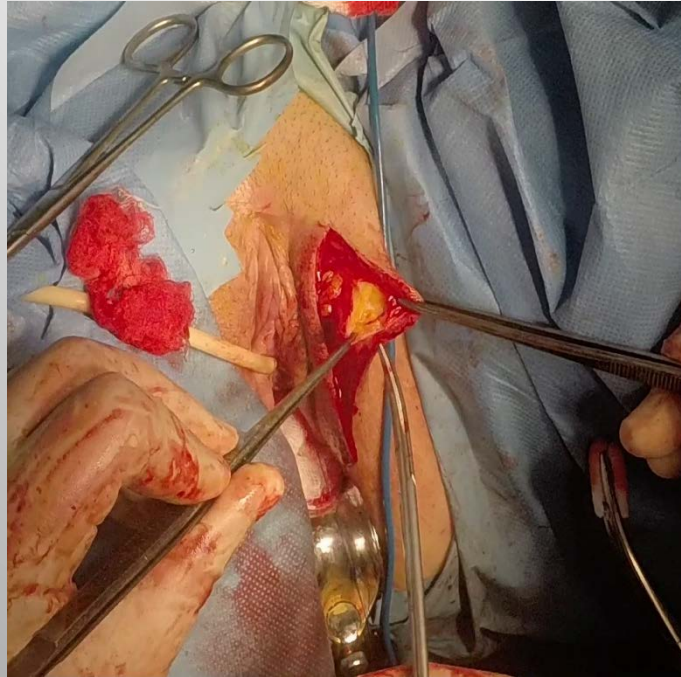
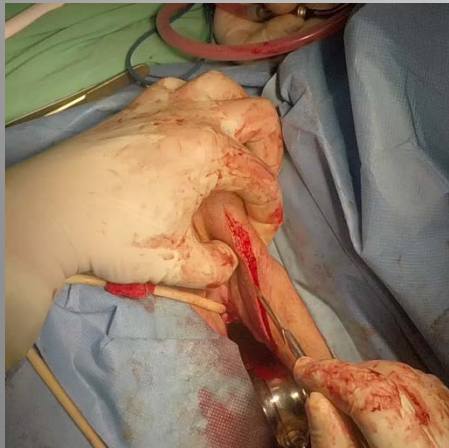
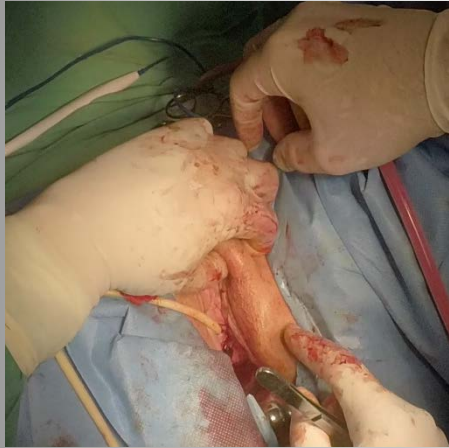Προβολή υλικού στο πρόσθιο
κολπικό τοίχωμα





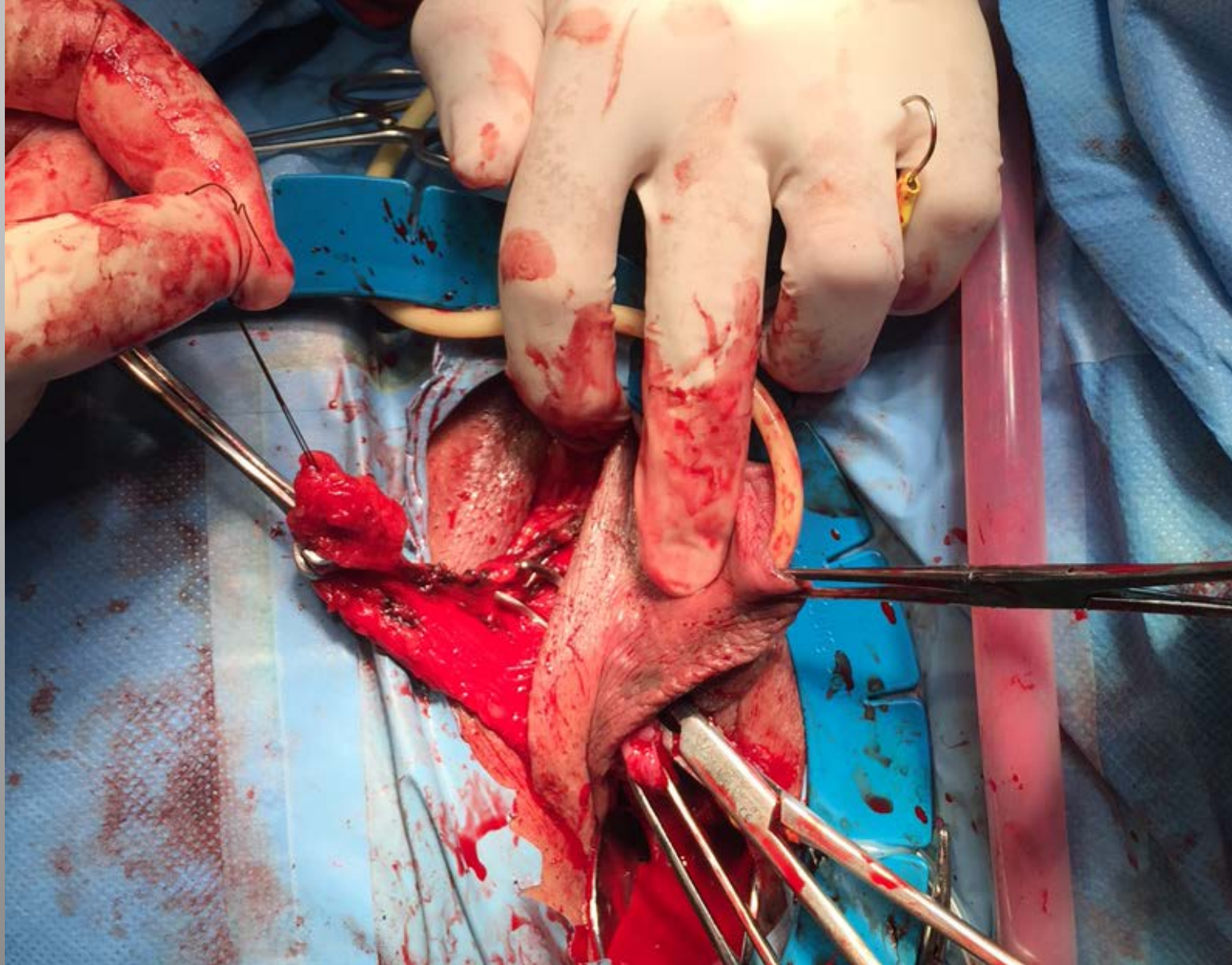
Martius flap



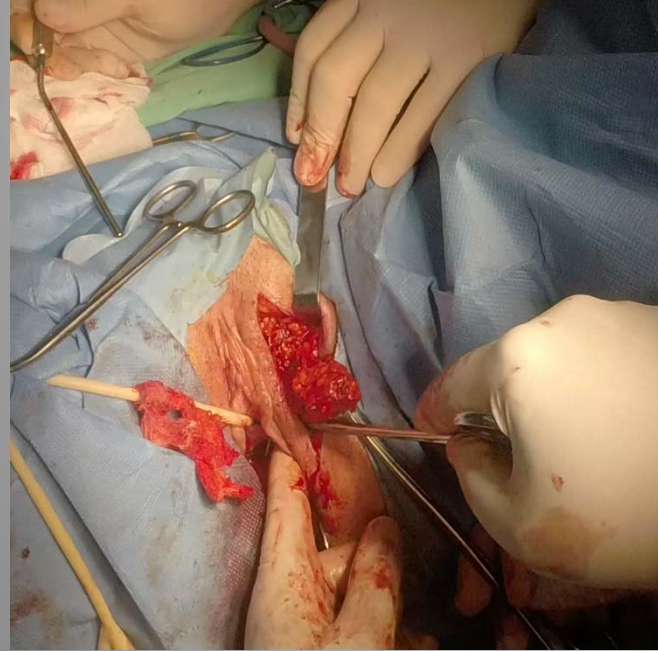
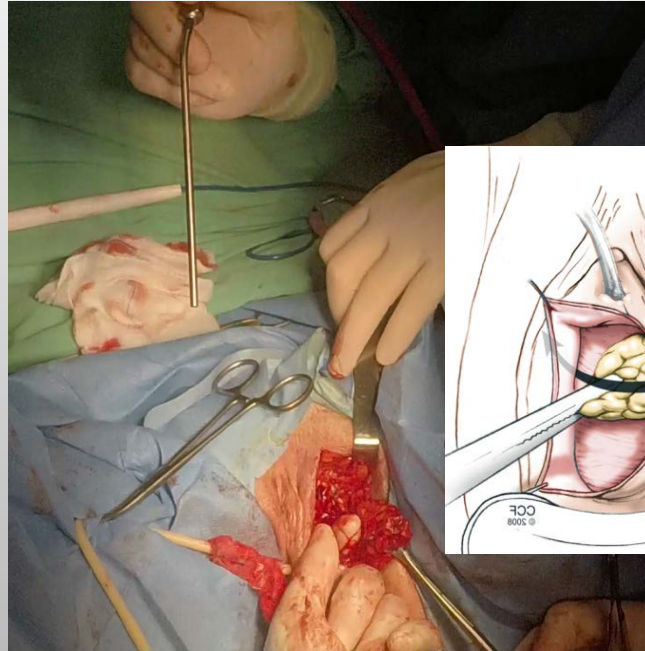
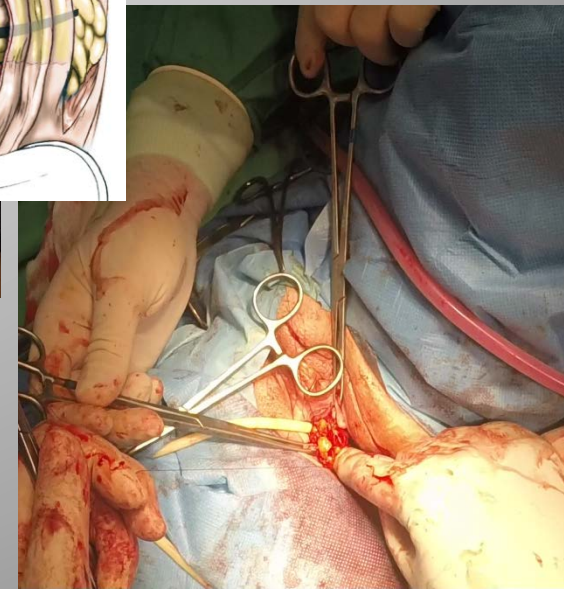
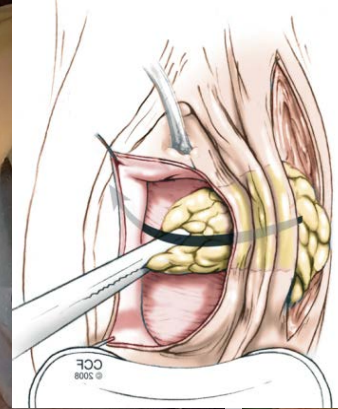
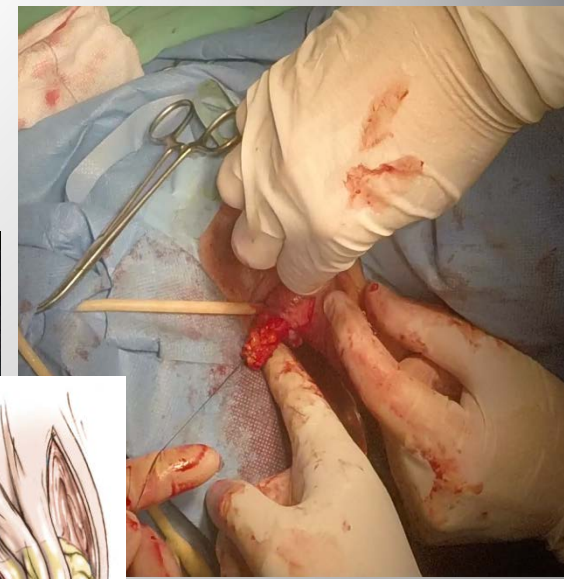


Lateral to medial adipose tissue dissection

Vertical incision after pedicle base marking

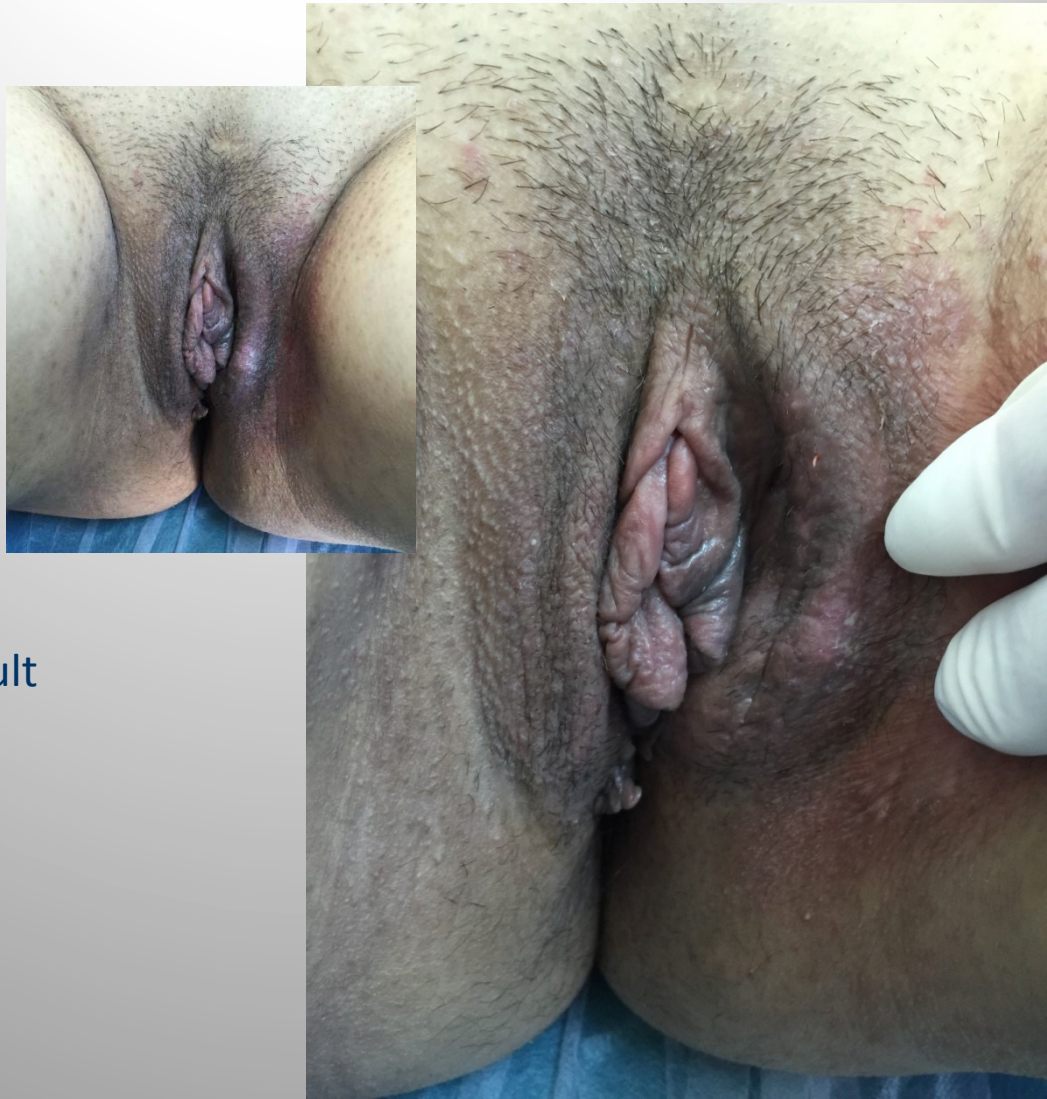

Tunneling of the flap at the base of the labial incision and interpositioning between the bladder and vaginal wall



The modified Martius flap

Preparation of the tunnel behind the labium minus and bulbocavernosus muscle



Cosmetic result

Ευχαριστώ για την προσοχή σας

